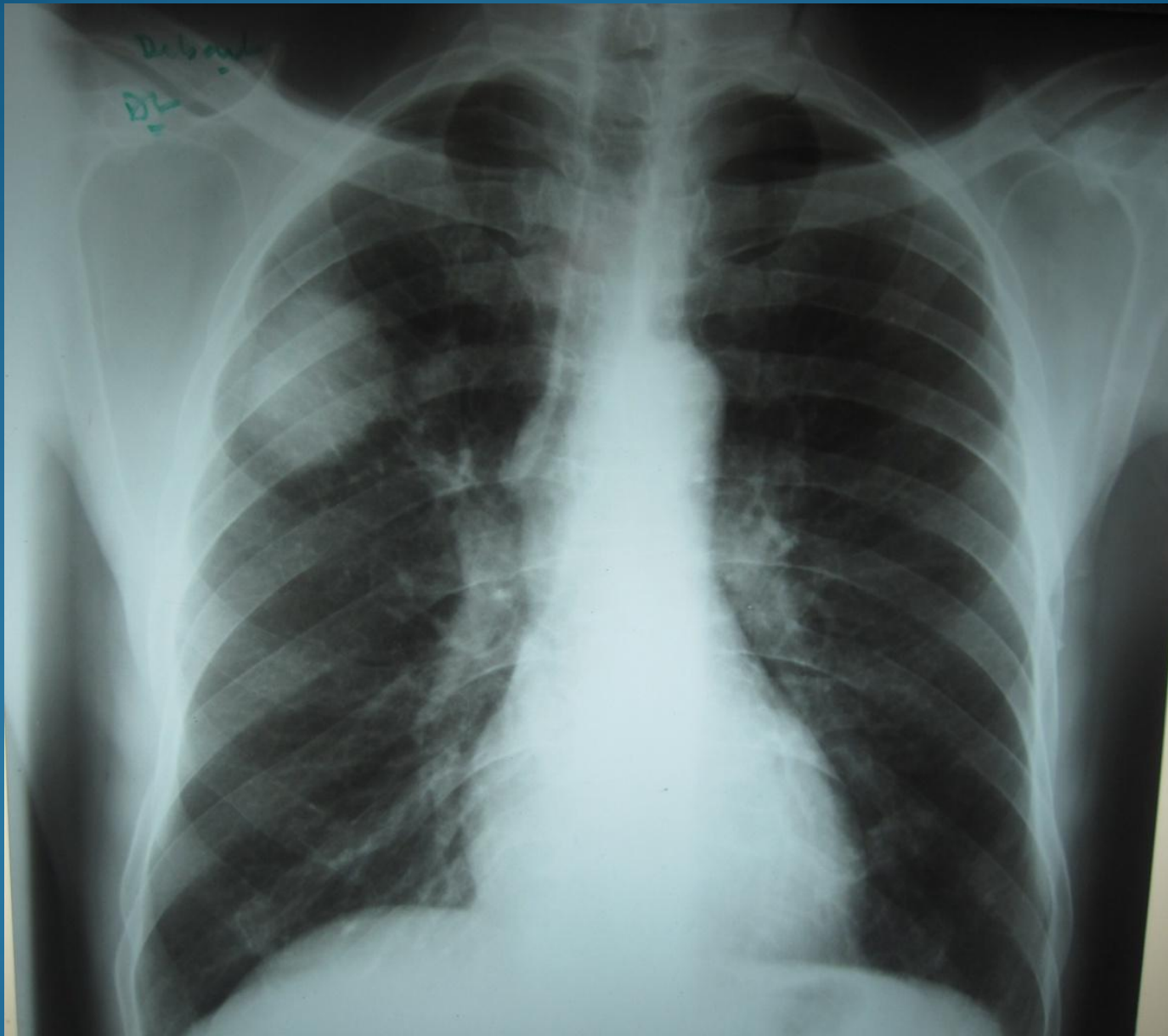


OBSERVATION 1

Cancer bronchique

- Mr M.H agé de 68 ans.
- Originaire de Kebili
- ATCD: ulcère gastroduodénal
- Tabac 10 paquet année.
- Douleur thoracique.

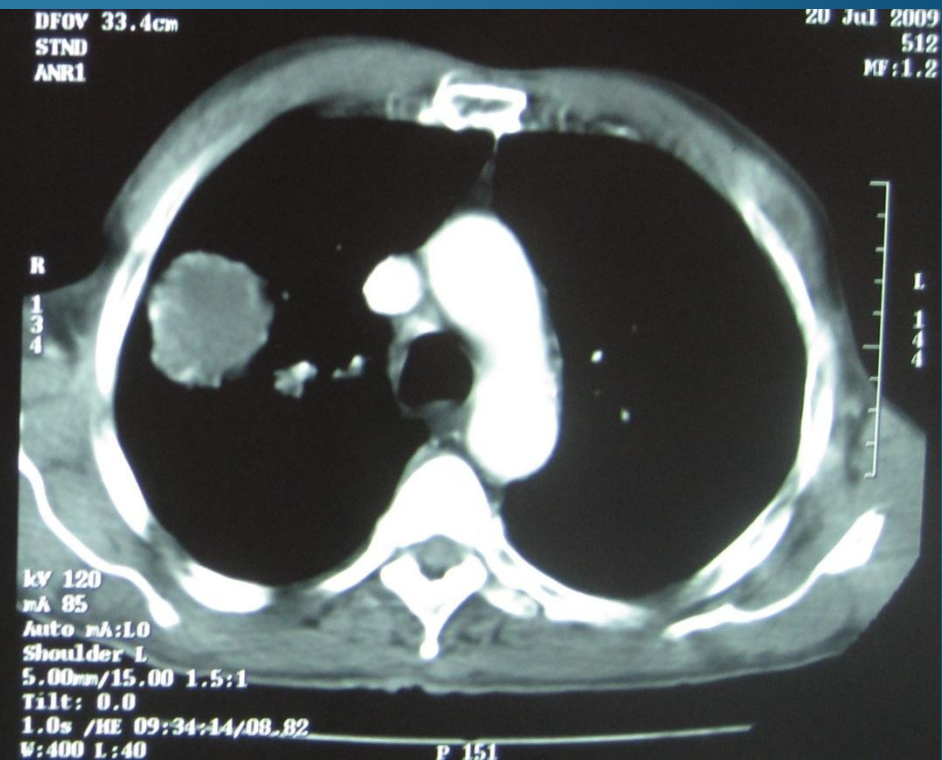
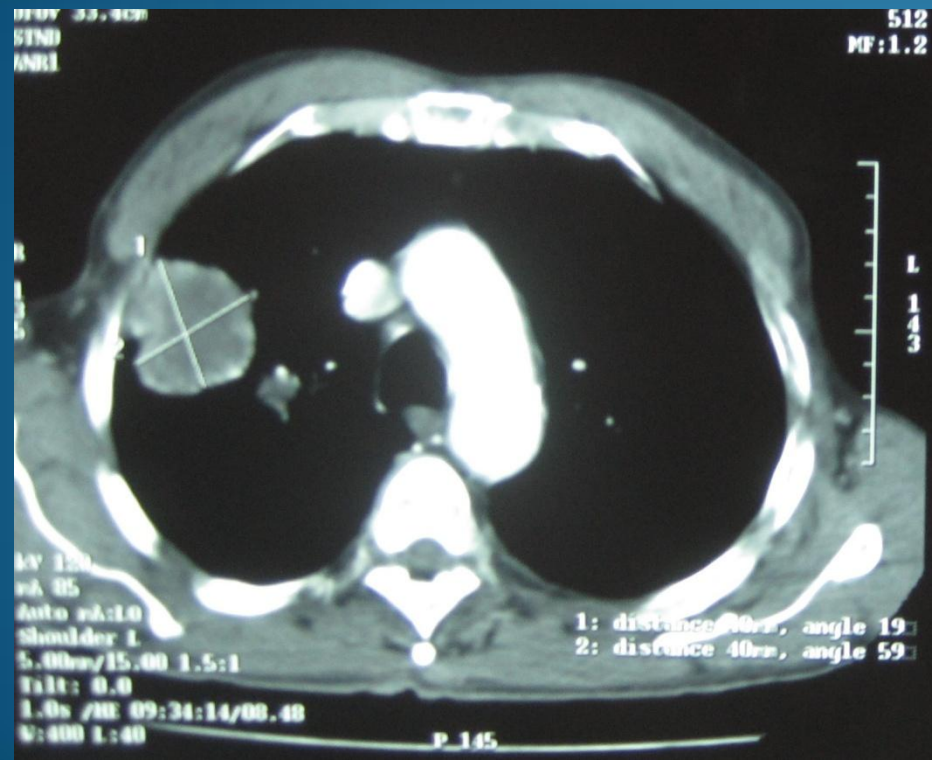
Radio Thorax



Scanner thoracique 07/ 2009

Lésion kystique de 4 cm à paroi épaisse et régulière du segment ventral du lobe supérieur droit présentant un contact pleural.

Abdomen: Kyste biliaire.



7225
104 RETRO
1139.00
115+C

FOV 33.4cm
TND
sd

MR MELOUDI HADDED
M 68 012007

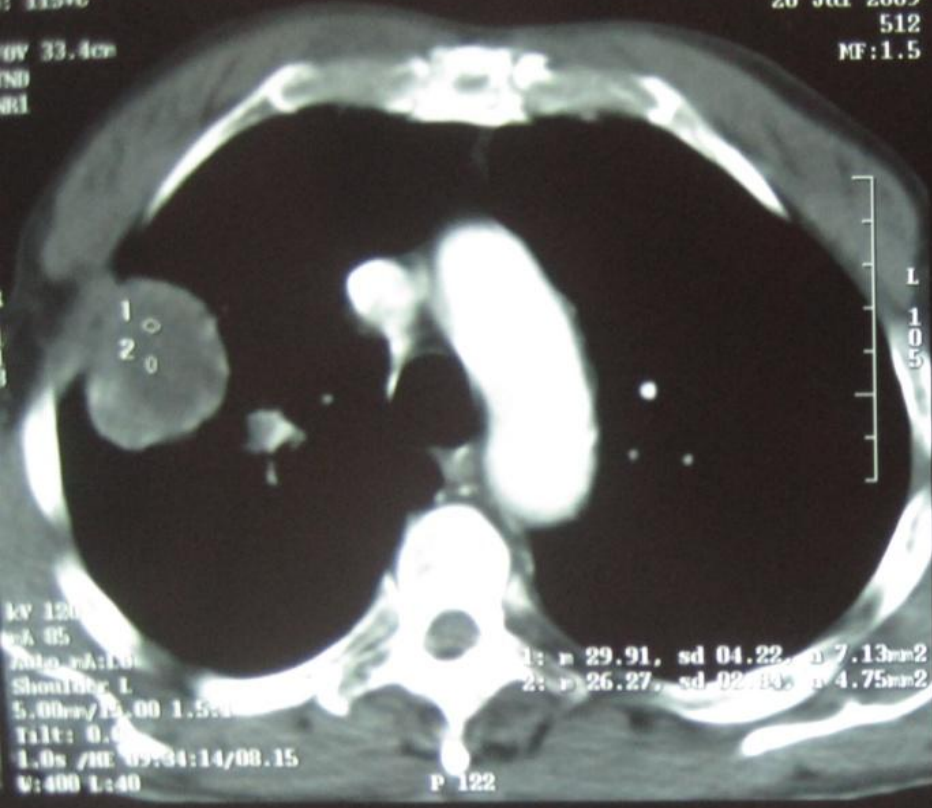20 Jul 2009
512
MF:1.5

Se: 104 RETRO
SN 1144.00
Im: 116+C

DFOV 33.4cm
STND
ANR1

MR MELOUDI HADDED
M 68 012007

20 Jul 2009
512
MF:1.5



kV 120
mA 85
Auto mA:LO
Shoulder L
5.00mm/15.00 1.5:0.0
Tilt: 0.0
1.0s /HE 09:34:14/00.15
V:400 L:40

1: m 29.91, sd 04.22, a 7.13mm2
2: m 26.27, sd 02.83, a 4.75mm2

L
1
0
5

R
1
1
8

kV 120
mA 85
Auto mA:LO
Shoulder L
5.00mm/15.00 1.5:0.0
Tilt: 0.0
1.0s /HE 09:34:14/08.48
V:400 L:40

1: m 26.00, sd 03.13, a 3.57mm2
2: m 18.89, sd 03.77, a 11.88mm2
3: m 17.49, sd 04.95, a 11.88mm2

L
1
0
5

R
1
1
8

kV
mA
Auto
Sh
5.
Ti
1.0
W:4

HiSpeed Dual SYS#CT
Ex: 7225
Se: 104 RETRO
SN I149.00
Im: 27+C

A 139

CLINIQUE BON SECOURS GABES

MR MLOUDI HADDED
M 68 012007

20 Jul 2009
512
MF:1.2

HiSpeed Dual SYS#CT

A 139

CLINIQUE BON SECOURS

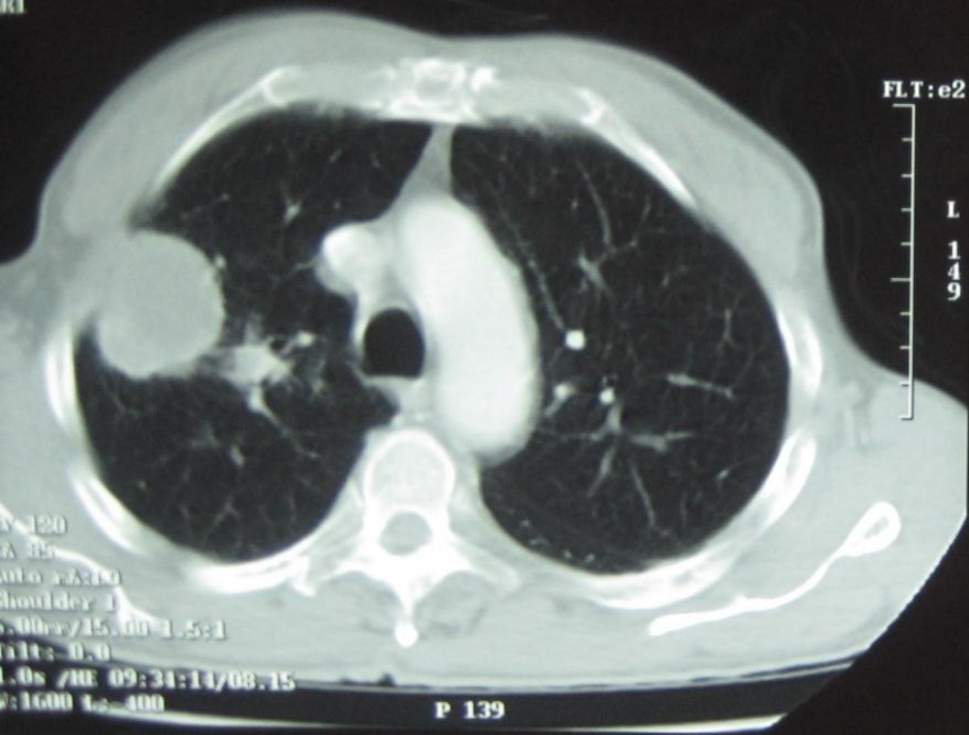
MR MLOUDI H
M 68

20 Ju

Ex: 7225
Se: 104 RETRO
SN I149.00
Im: 27+C

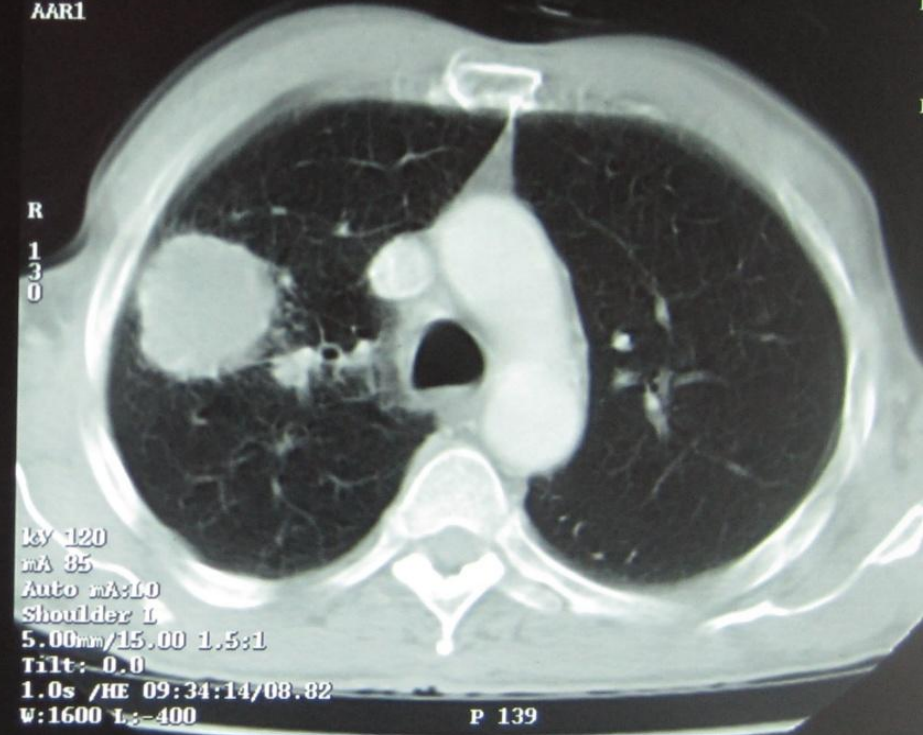
DFOV 33.4cm
CHST
AAR1

DFOV 33.4cm
CHST
AAR1



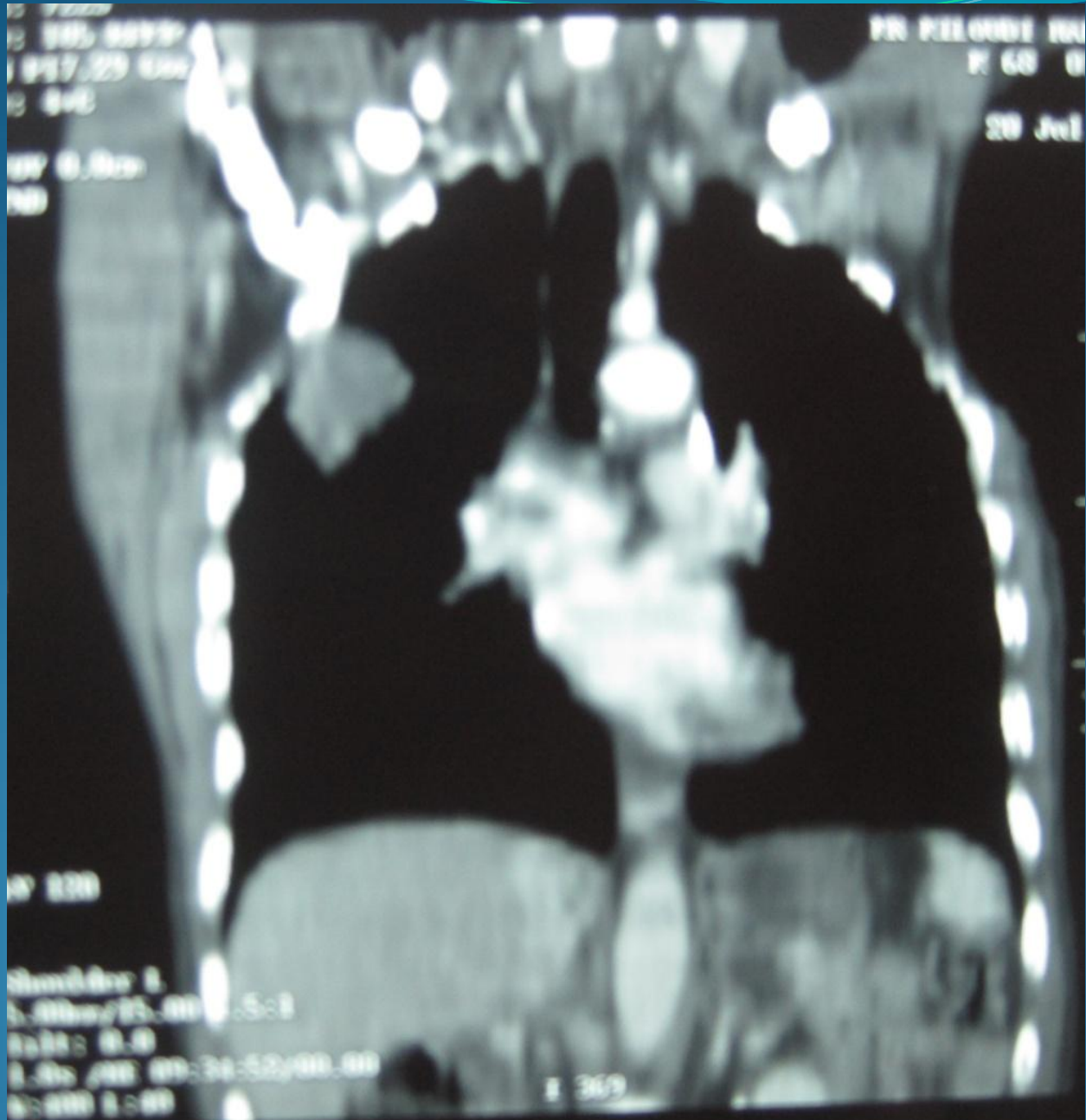
KV 120
mA 85
Auto mA:10
Shoulder I
5.00mm/15.00 1.5:1
Tilt: 0.0
1.0s /HE 09:34:14/08.15
V:1600 Lz:400

P 139

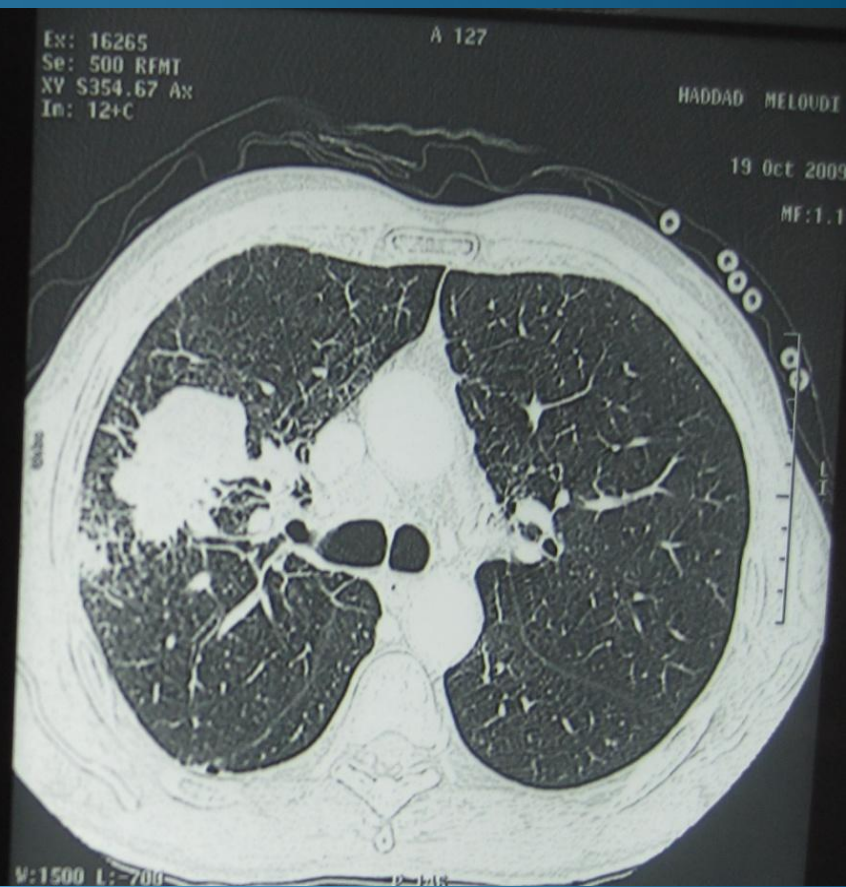
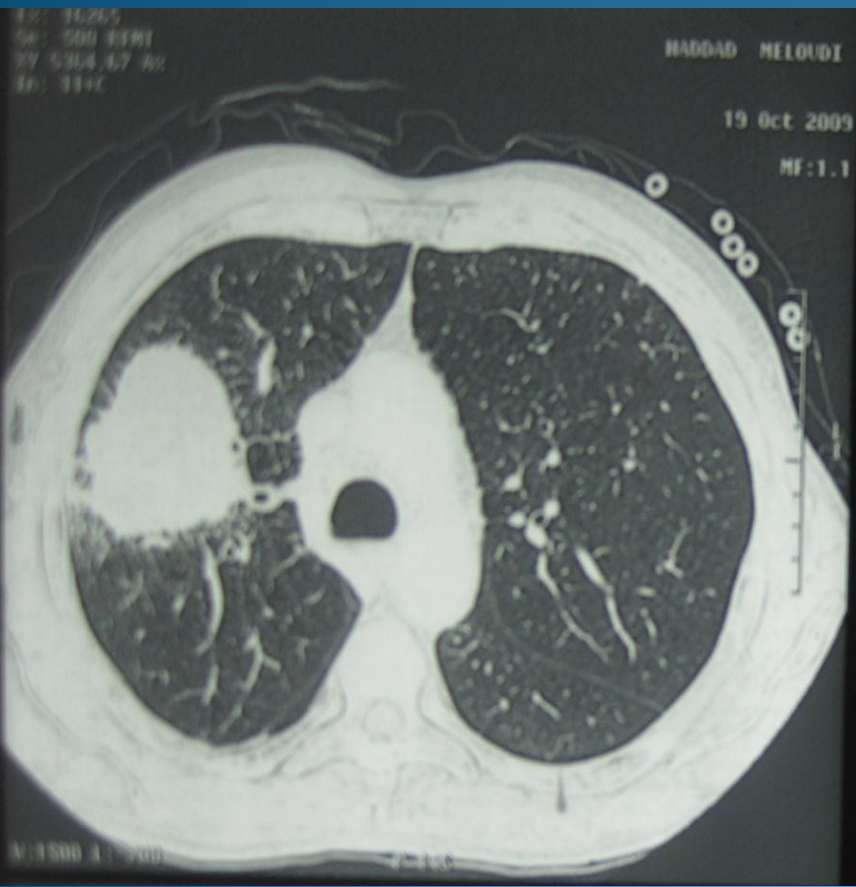


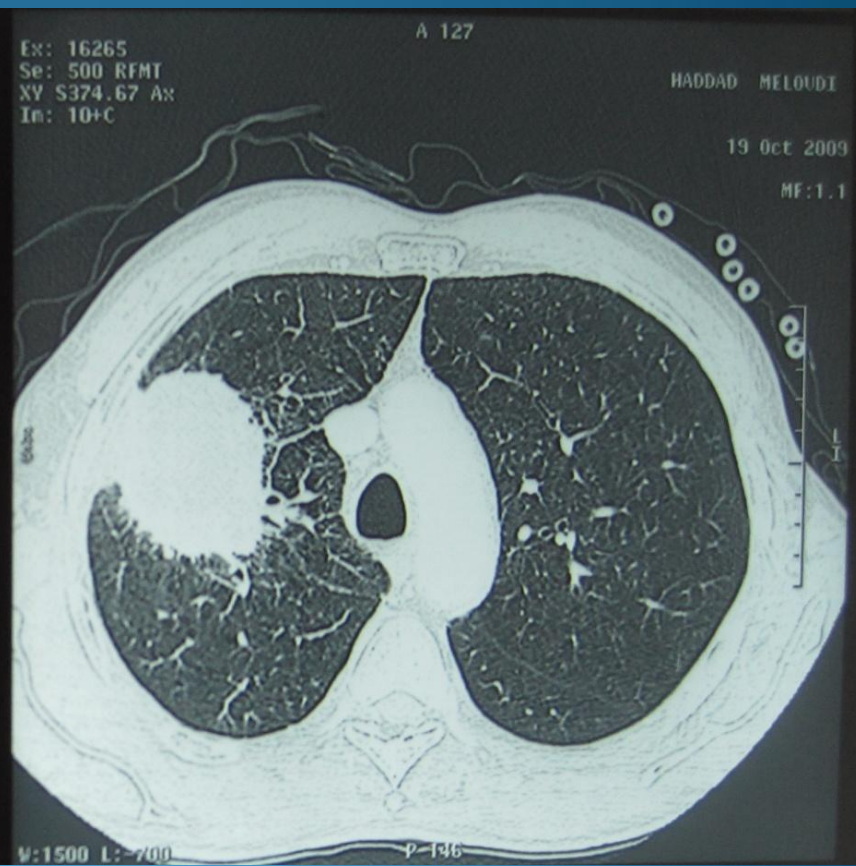
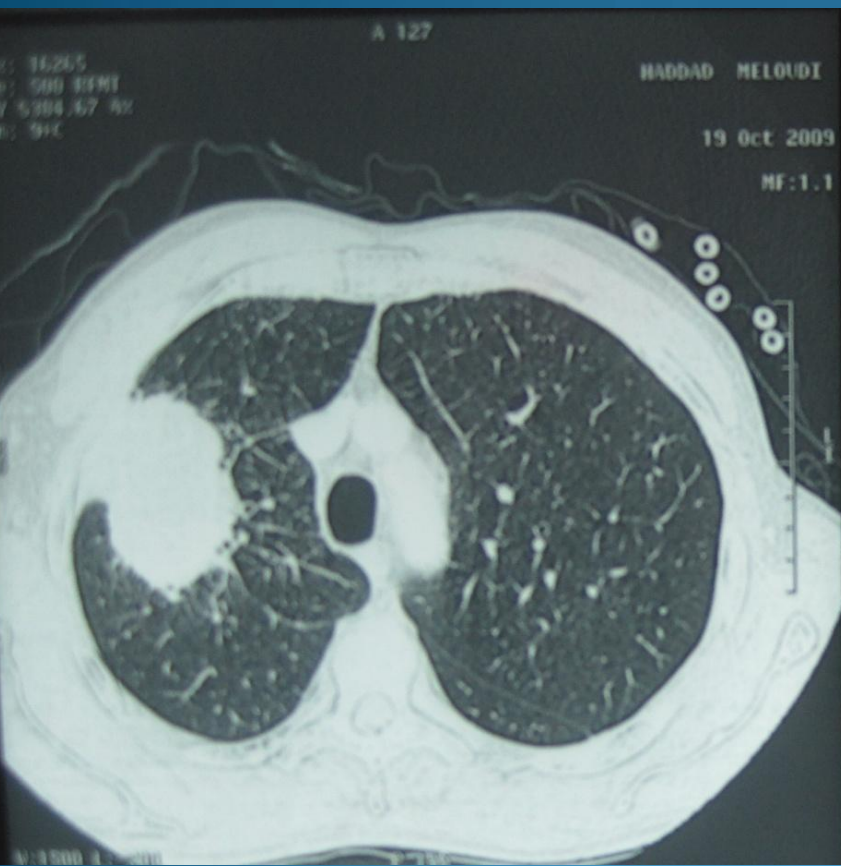
KV 120
mA 85
Auto mA:10
Shoulder I
5.00mm/15.00 1.5:1
Tilt: 0.0
1.0s /HE 09:34:14/08.82
V:1600 Lz:400

P 139



- Pas de prise en charge spécifique.
- Aggravation des douleurs.
- TDM (10/2009): masse tissulaire LSD périphérique avec envahissement de la graisse extrapleurale sans lyse osseuse, ADP hilaires et sous carinaires
Nodule surrénalien gauche





Biopsie sous scanner:

Carcinome épidermoïde bien différencié

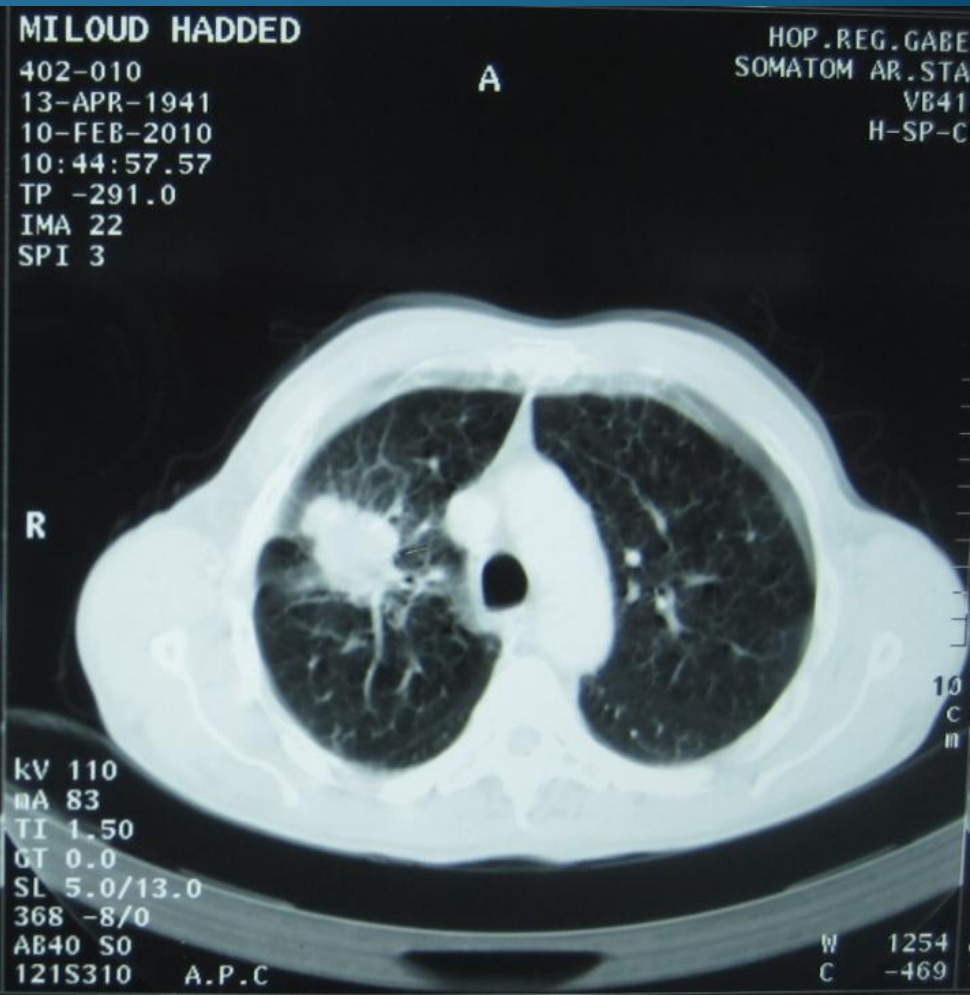
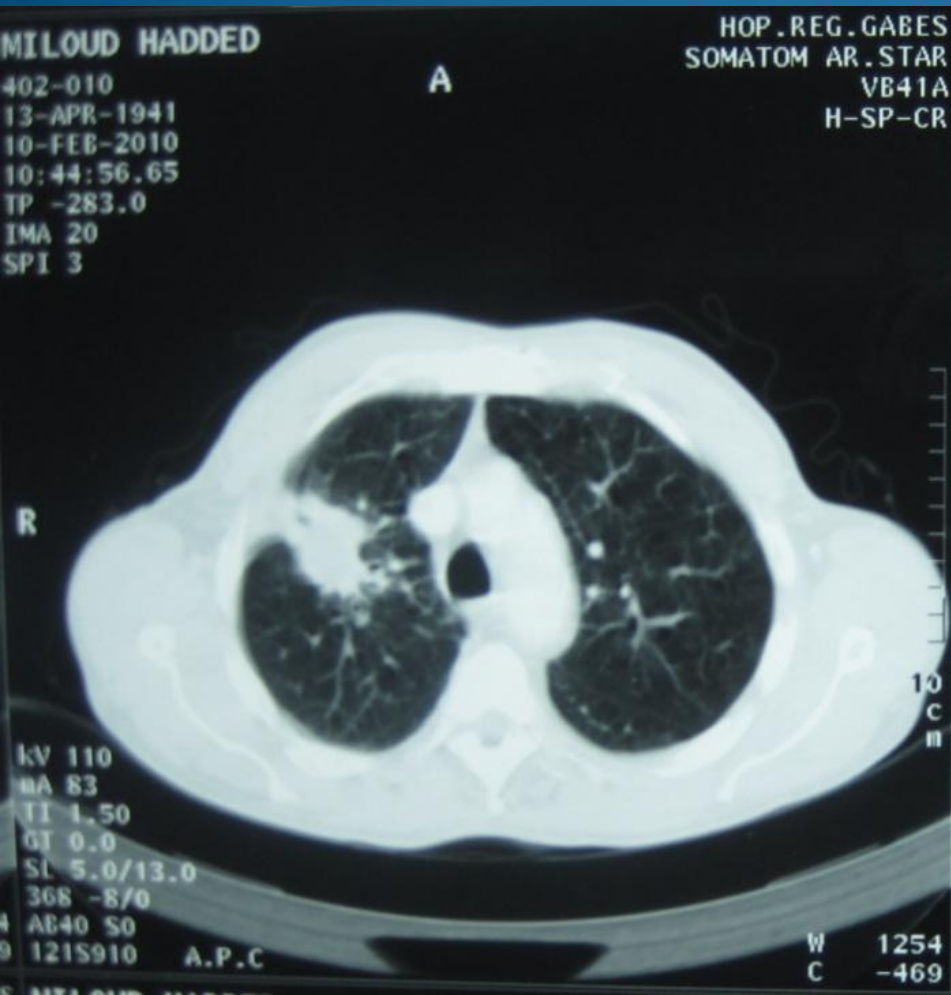
Kératinisant

T3N2M1

Chimiothérapie 2 cycles VP16 cisplatine

2 cycles Navelbine cisplatine

TDM après chimiothérapie



MILOUD HADDED

402-010
13-APR-1941
10-FEB-2010
10:44:57.12
TP -287.0
IMA 21
SPI 3

A

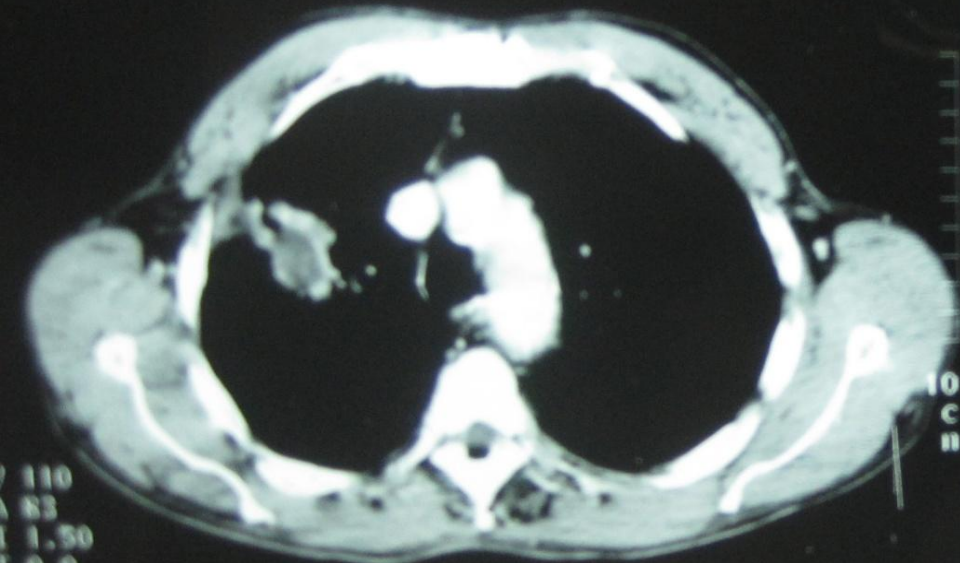
HOP.REG.GABES
SOMATOM AR.STAR
VB41A
H-SP-CR

MILOUD HADDED

402-010
13-APR-1941
10-FEB-2010
10:44:57.12
TP -287.0
IMA 21
SPI 3

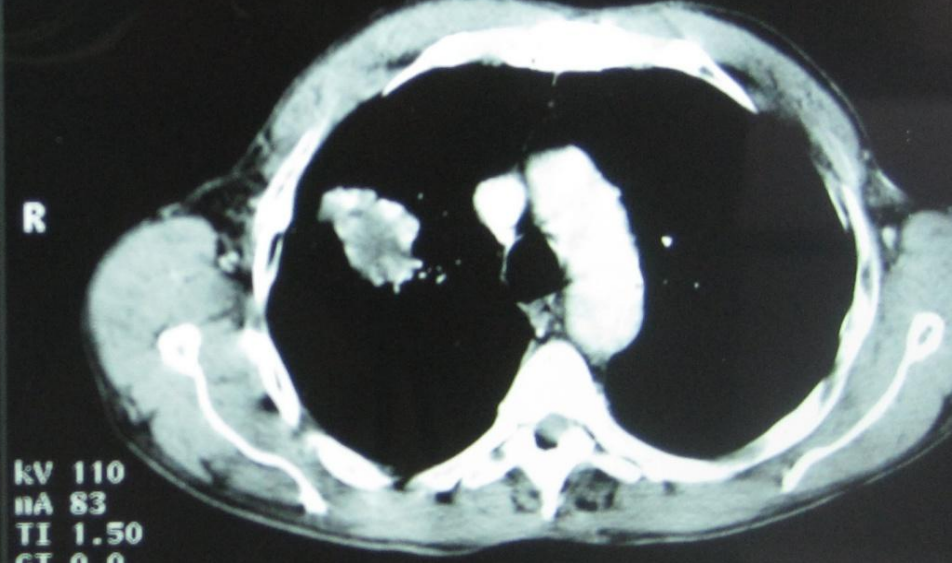
A

HOP.REG.
SOMATOM AR
H-



kV 110
mA 83
TI 1.50
GT 0.0
SL 5.0/13.0
368 -8/0
AB40 S0
121S610 A.P.C

W 200
C 50



kV 110
mA 83
TI 1.50
GT 0.0
SL 5.0/13.0
368 -8/0
AB40 S0
121S610 A.P.C

W 200
C 50

MILOU HADDED

402-010
13-APR-1941
10-FEB-2010
10:44:55.28
TP -275.0
IMA 18
SPI 3

A

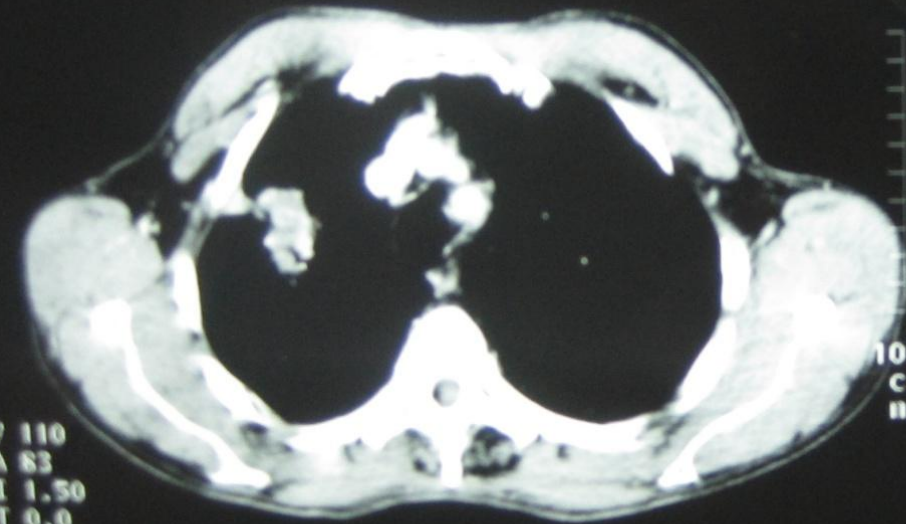
HOP. REG. GABES
SOMATOM AR. STAR
VB41A
H-SP-CR

MILOU HADDED

402-010
13-APR-1941
10-FEB-2010
10:44:55.74
TP -275.0
IMA 18
SPI 3

A

HOP. REG. GABES
SOMATOM AR. STAR
VB41A
H-SP-CR

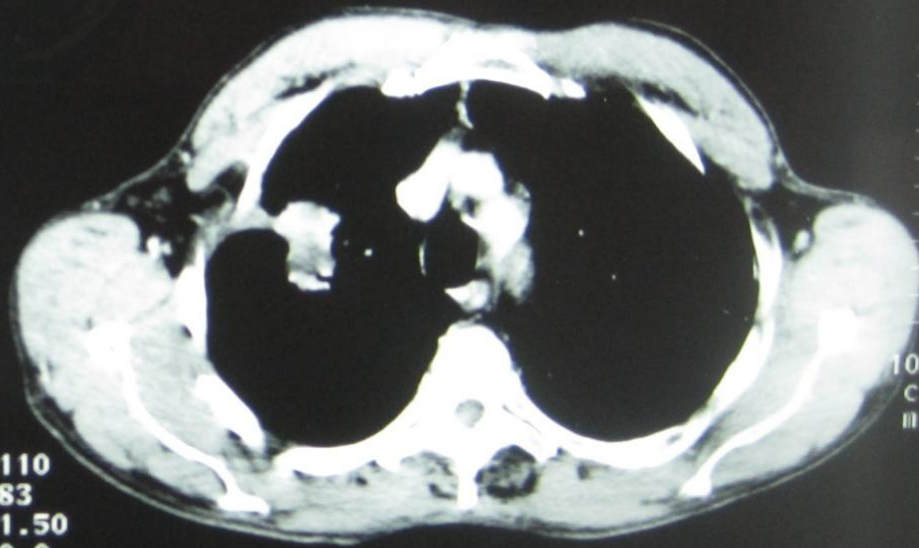


10
C
II

kV 110
mA 83
TI 1.50
GT 0.0
SL 5.0/13.0
368 -8/0
1840 50

R

kV 110
mA 83
TI 1.50
GT 0.0
SL 5.0/13.0
368 -8/0
1840 50

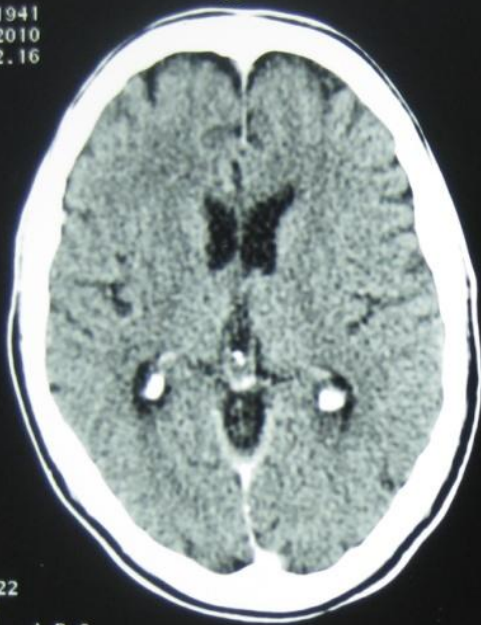

10
C
II

W 200

MILOUD HADDED

402-010
13-APR-1941
10-FEB-2010
10:54:32.16
TP 6.0
IMA 112
SEQ 17

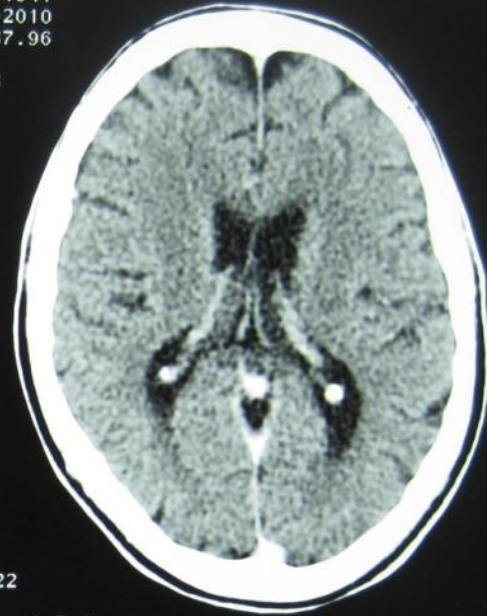


110
83
1.5
0.0
5.0
220 0/-22
AH41 S0
01 370 A.P.C

HOP.REG.GABES
SOMATOM AR.STAR
VB41A
H-SP-CR

MILOUD HADDED

402-010
13-APR-1941
10-FEB-2010
10:54:37.96
TP 6.0
IMA 113
SEQ 18

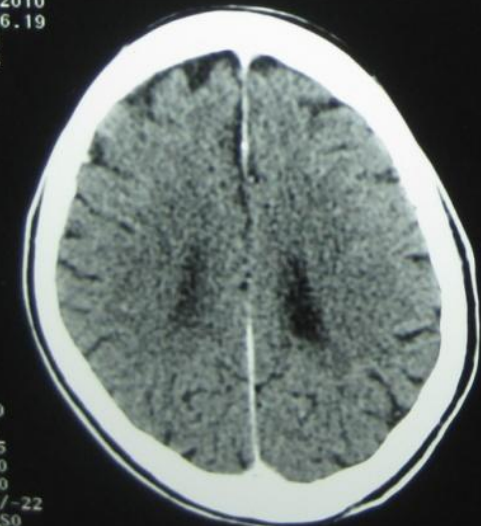


110
83
1.5
0.0
5.0
220 0/-22
AH41 S0
001 370 A.P.C

HOP.REG.GABES
SOMATOM AR.STAR
VB41A
H-SP-CR

MILOUD HADDED

402-010
13-APR-1941
10-FEB-2010
10:54:56.19
TP 21.0
IMA 116
EQ 21

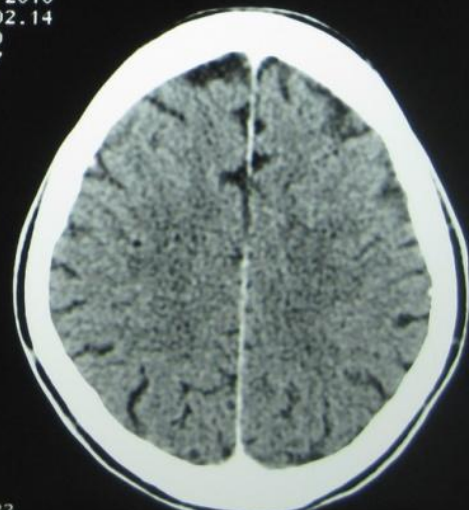


110
83
1.5
0.0
5.0
220 0/-22
AH41 S0

HOP.REG.GABES
SOMATOM AR.STAR
VB41A
H-SP-CR

MILOUD HADDED

402-010
13-APR-1941
10-FEB-2010
10:55:02.14
TP 26.0
IMA 117
SEQ 22



110
83
1.5
0.0
5.0
220 0/-22

HOP.REG.GABES
SOMATOM AR.STAR
VB41A
H-SP-CR

Opéré le 25/03/10

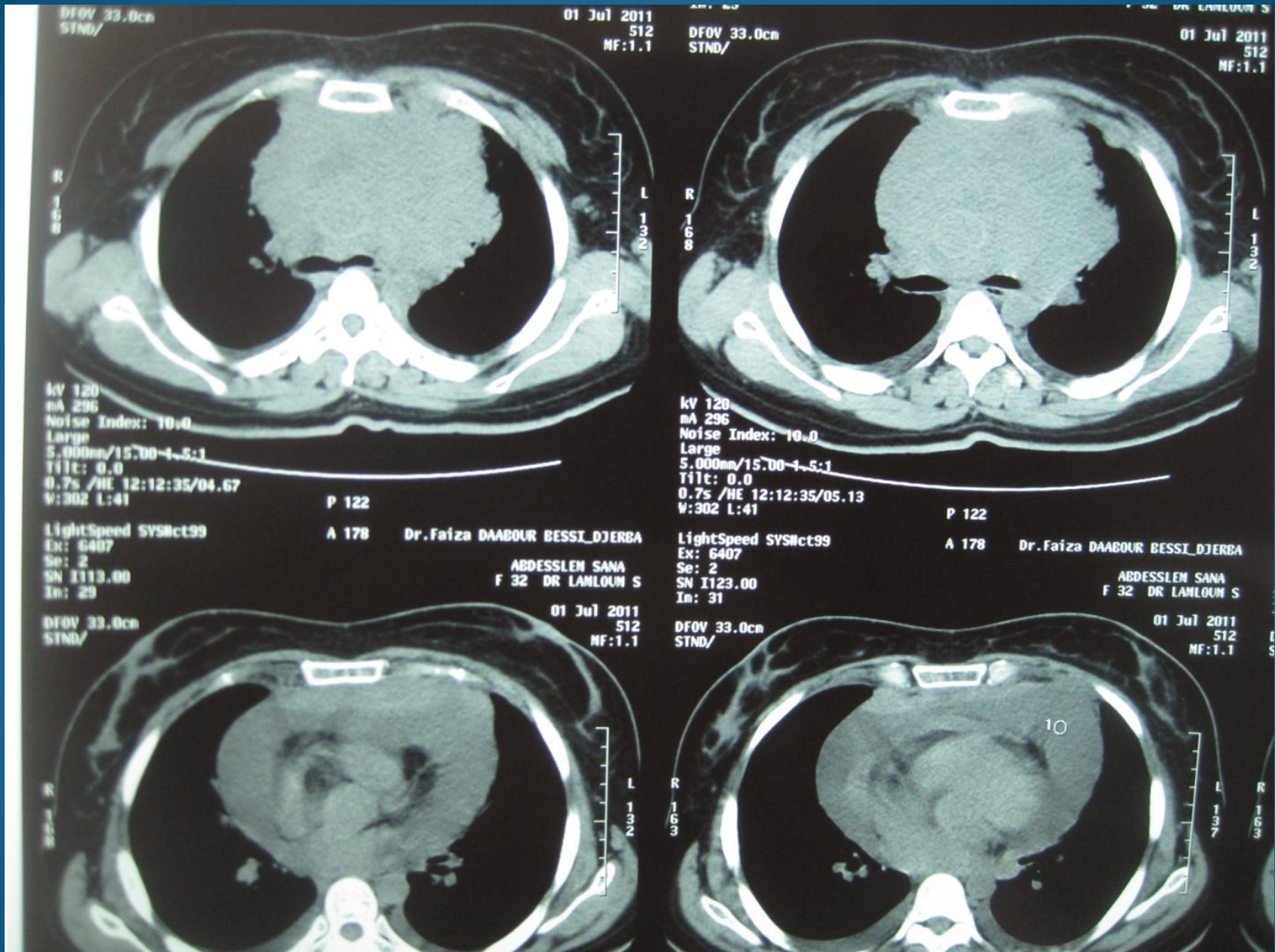
- Lobectomie supérieure droite élargie a la plèvre pariétale + curage gg.
- Carcinome épidermoïde bien différencié du LSD de 4 cm.
plèvre, recoupes bronchiques Vasculaires saines
13 ganglions négatifs
Tuberculose ganglionnaire active

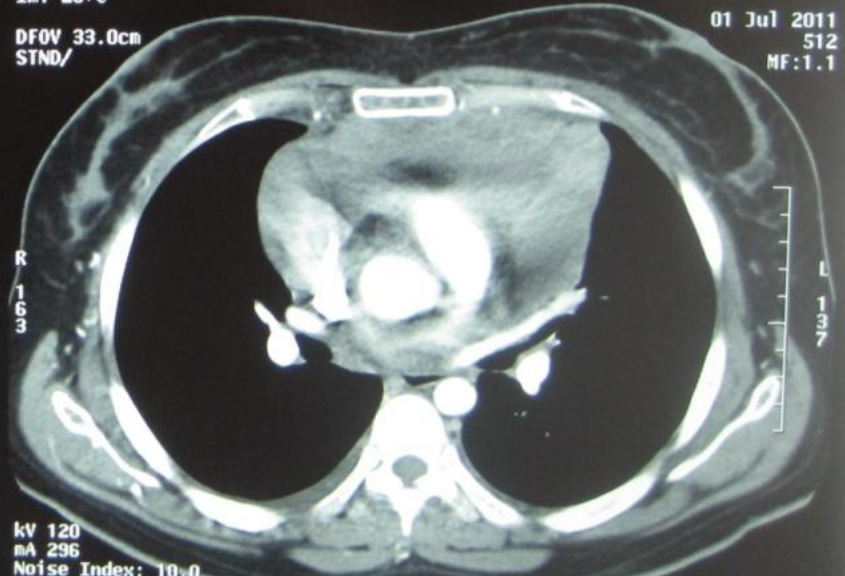
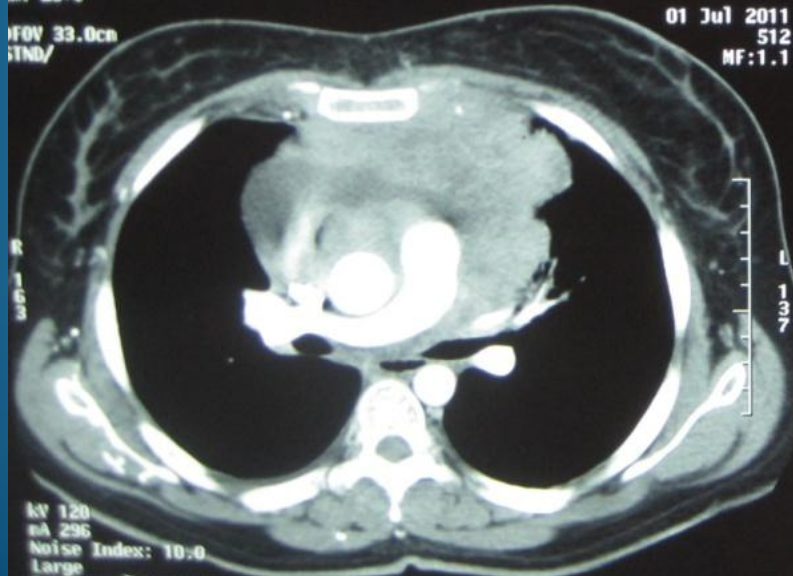
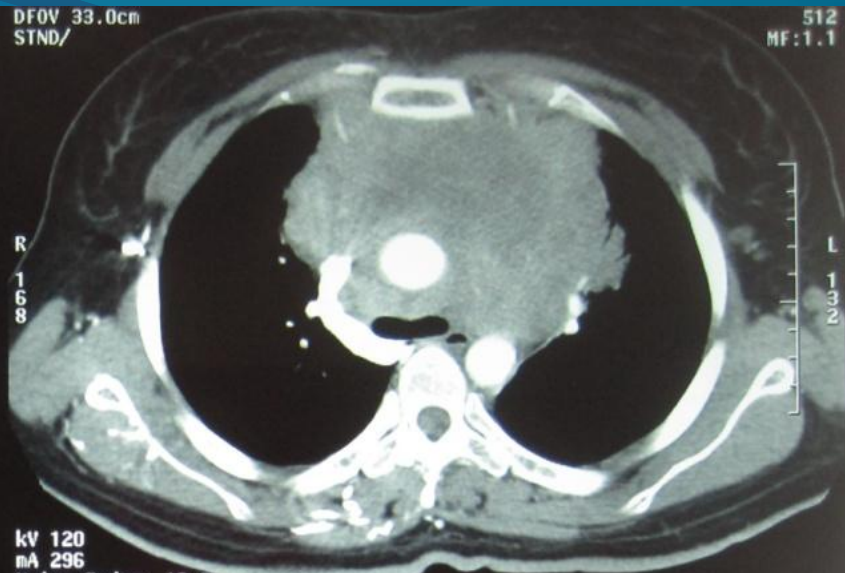
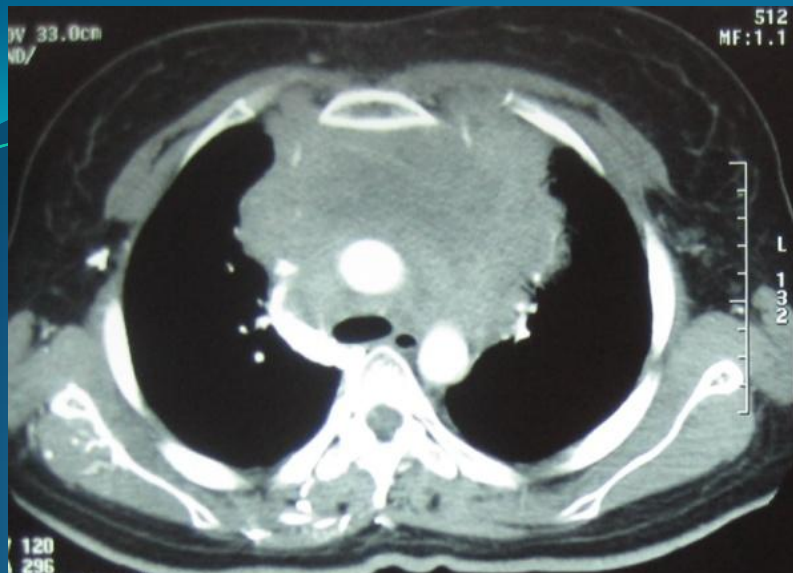
OBSERVATION 2

Tumeur médiastinale

- Mlle S.A agée de 32 ans.
- Originaire de Zarzis.
- Sans ATCDs particuliers.
- Toux dyspnée douleurs thoraciques .
- OMS= 0 , syndrome cave supérieur

TDM 07/2011





P 129

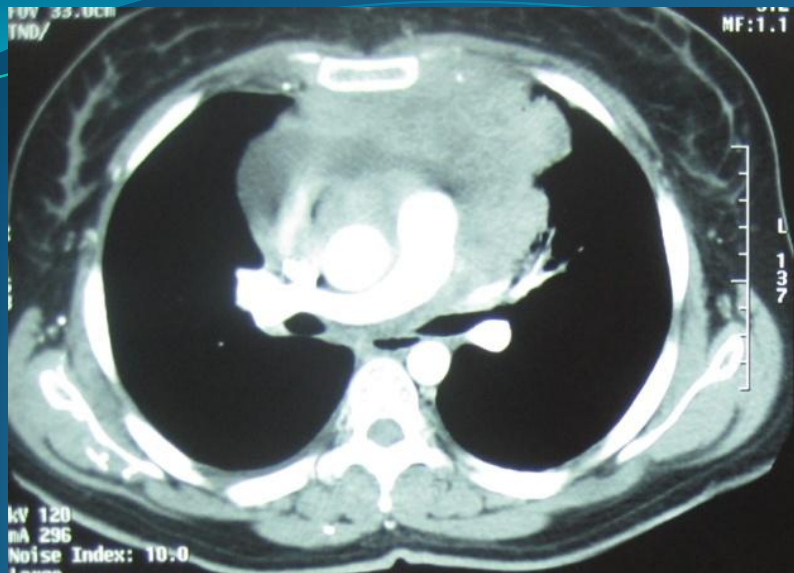
P 129

A 177 Dr.Faiza DAABOUR BESSI_DJERBA

A 177 Dr.Faiza DAABOUR BESSI_DJERBA

ABDESSLEM SANA
F 32 DR LAMLOUM S

ABDESSLEM SANA
F 32 DR LAMLOUM S



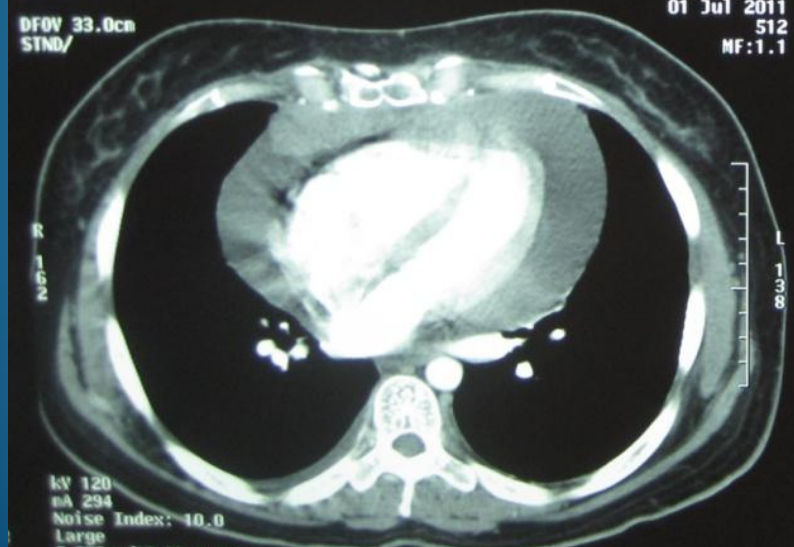
DFOV 33.0cm
STND/
MF:1.1
512
kV 120
mA 296
Noise Index: 10.0
Large
5.000mm/15.00-1.5:1
Tilt: 0.0
0.7s /HE 12:15:48/05.83
V:349 L:45

P 123

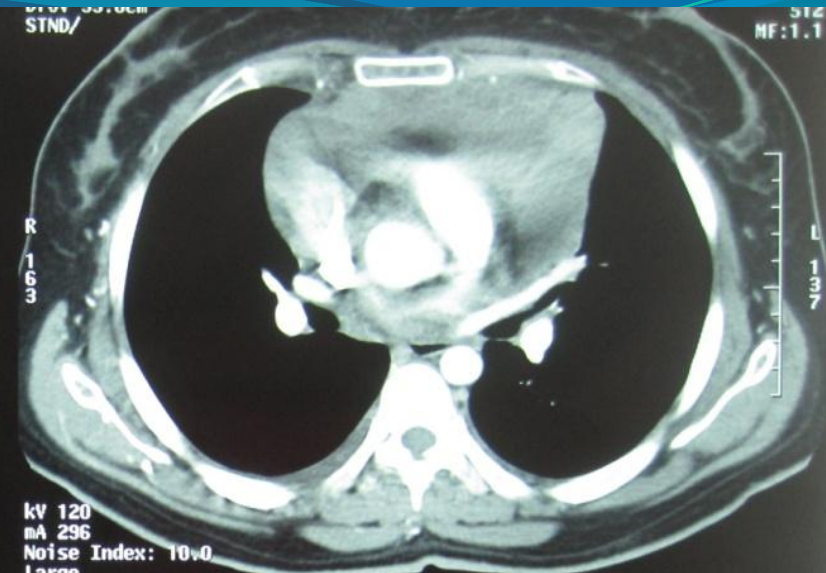
LightSpeed VSY#ct99
Ex: 6407
Se: 4
SN I138.00
In: 34+C

A 182 Dr.Faiza DAABOUR BESSI_DJERBA
ABDESLEM SANA
F 32 DR LAMLOUM S

01 Jul 2011



DFOV 33.0cm
STND/
MF:1.1
512
kV 120
mA 294
Noise Index: 10.0
Large
5.000mm/15.00-1.5:1



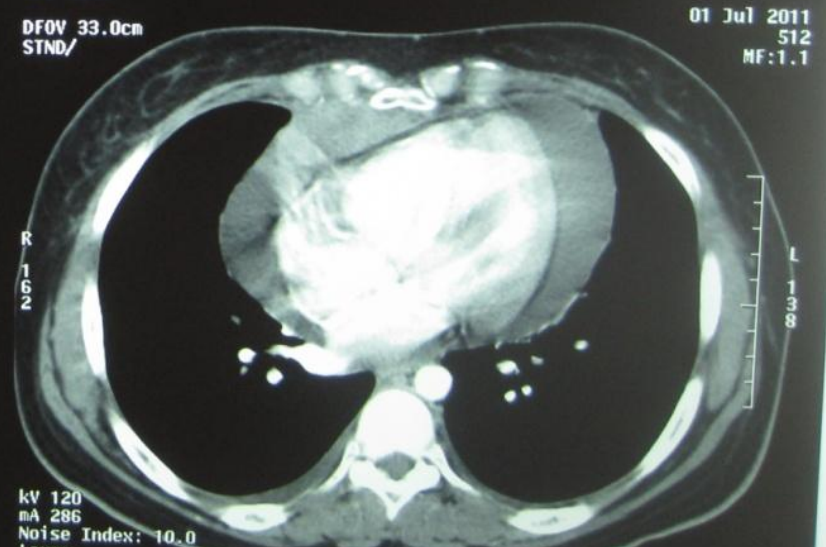
DFOV 33.0cm
STND/
MF:1.1
512
kV 120
mA 296
Noise Index: 10.0
Large
5.000mm/15.00-1.5:1
Tilt: 0.0
0.7s /HE 12:15:48/06.30
V:349 L:45

P 123

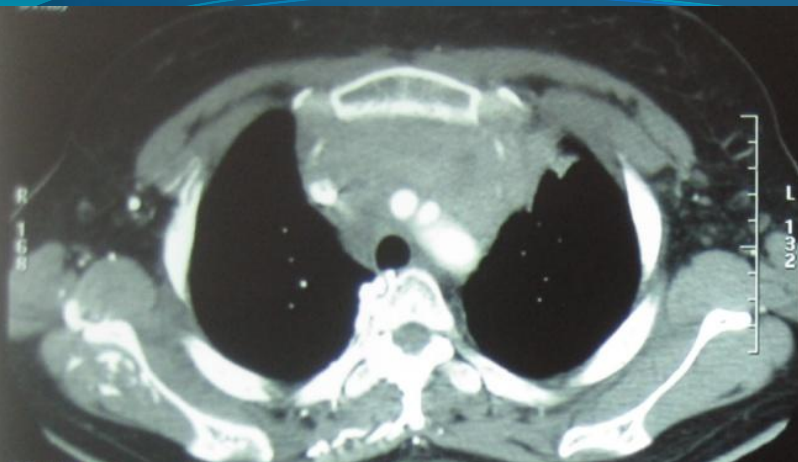
LightSpeed VSY#ct99
Ex: 6407
Se: 4
SN I148.00
In: 36+C

A 182 Dr.Faiza DAABOUR BESSI_DJERBA
ABDESLEM SANA
F 32 DR LAMLOUM S

01 Jul 2011



DFOV 33.0cm
STND/
MF:1.1
512
kV 120
mA 286
Noise Index: 10.0
Large



kV 120
mA 296
Noise Index: 10.0
Large
5.000mm/15.00 1.5:1
Tilt: 0.0
0.7s /HE 12:15:48/03.50
V:349 L:45

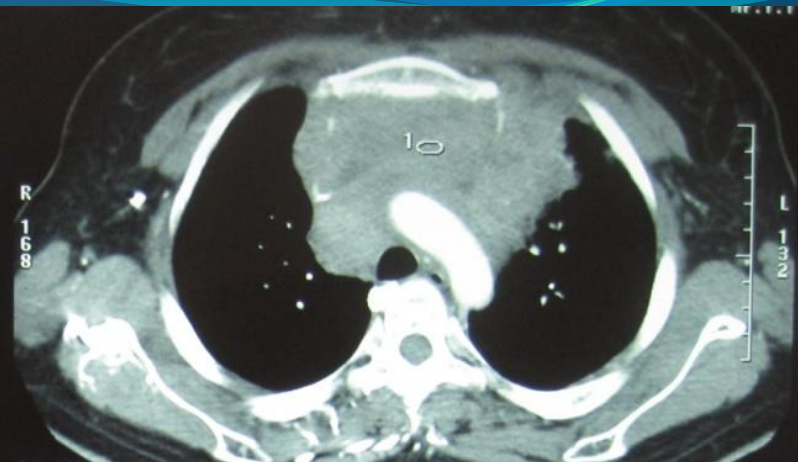
P 129

LightSpeed SYS#ct99
Ex: 6407
Se: 4
SN 183.00
In: 23+C

A 171 Dr.Faiza DAABOUR BESSI_DJERBA
ABDESSEM SANA
F 32 DR LAMLOUM S

01 Jul 2011
512
MF:1.1

DFOV 33.0cm
STND/



kV 120
mA 296
Noise Index: 10.0
Large
5.000mm/15.00 1.5:1
Tilt: 0.0
0.7s /HE 12:15:48/03.97
W:349 L:45

1: m 62.86, sd 12.69 -a 34.51mm2

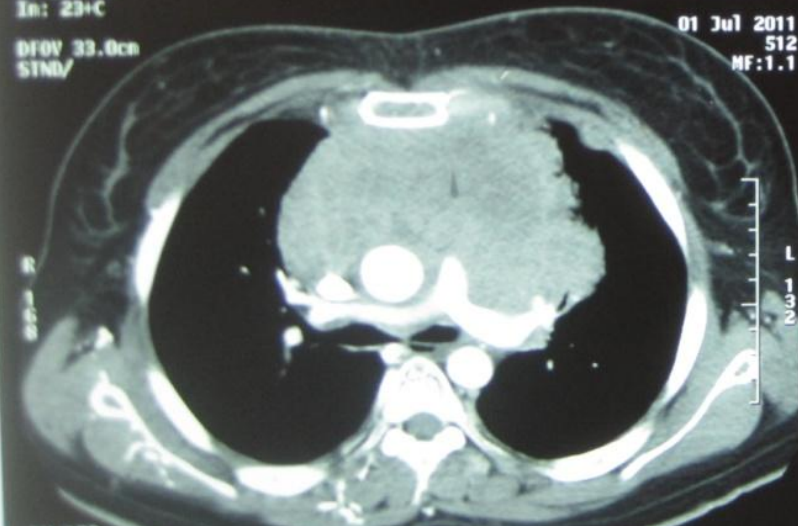
P 129

LightSpeed SYS#ct99
Ex: 6407
Se: 4
SN 193.00
In: 25+C

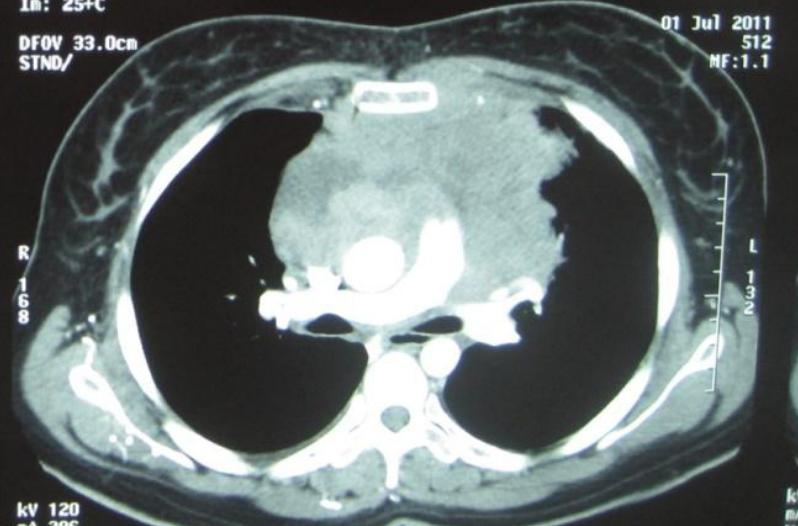
A 171 Dr.Faiza DAABOUR BESSI_DJERBA
ABDESSEM SANA
F 32 DR LAMLOUM S

01 Jul 2011
512
MF:1.1

DFOV 33.0cm
STND/



kV 120
mA 296
Noise Index: 10.0



kV 120
mA 296
Noise Index: 10.0
Large
5.000mm/15.00 1.5:1

kV 120
mA 296
Noise Index: 10.0
Large
5.000mm

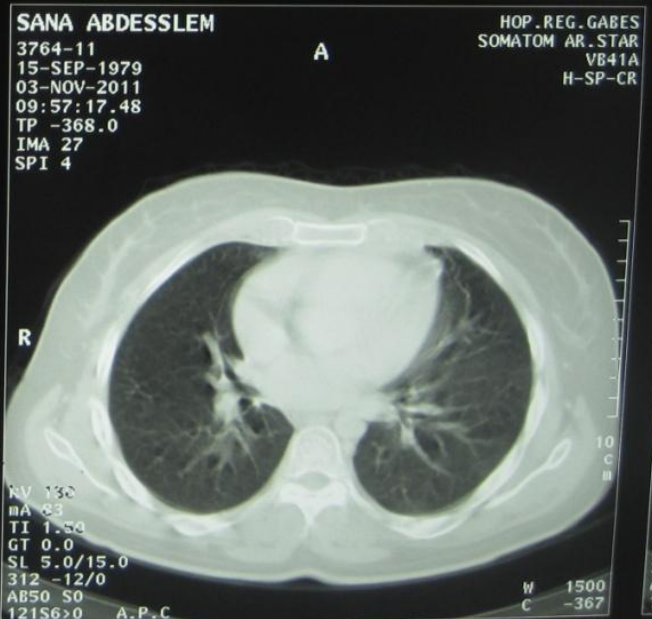
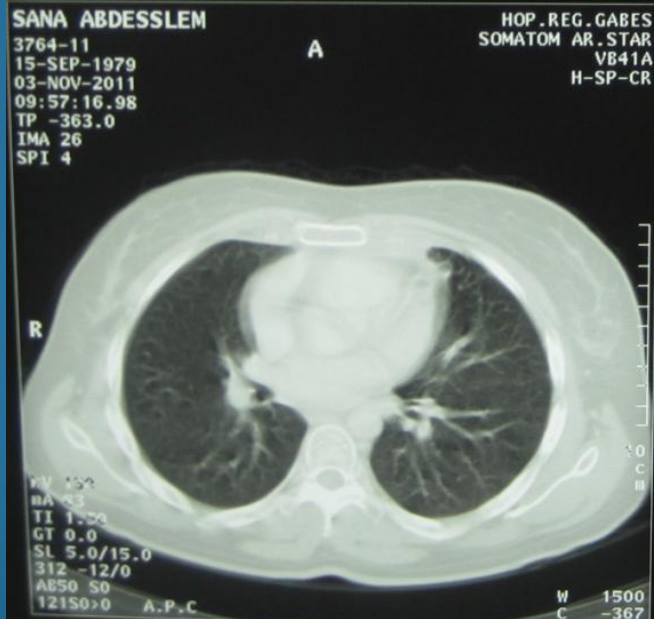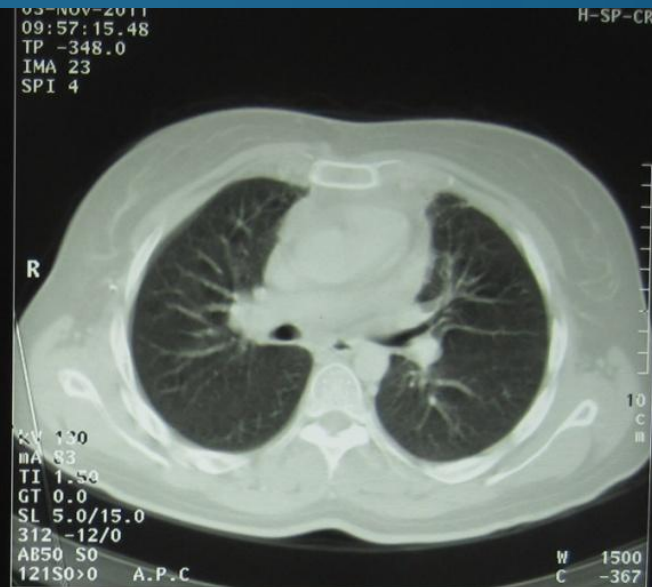
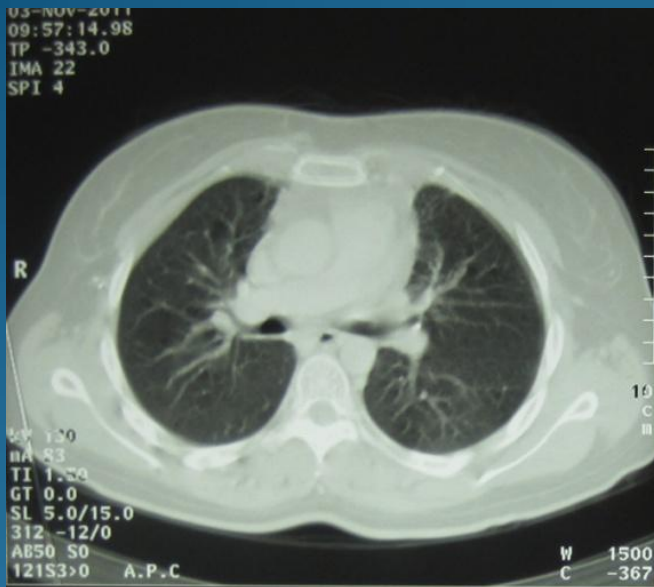
Biopsie chirurgicale

- Lymphome a grandes cellules B du médiastin CD20+
- Pas d'adénopathies périphériques
échographie abdominale normale
Biopsie médullaire normale
LDH normale

Stade et traitement

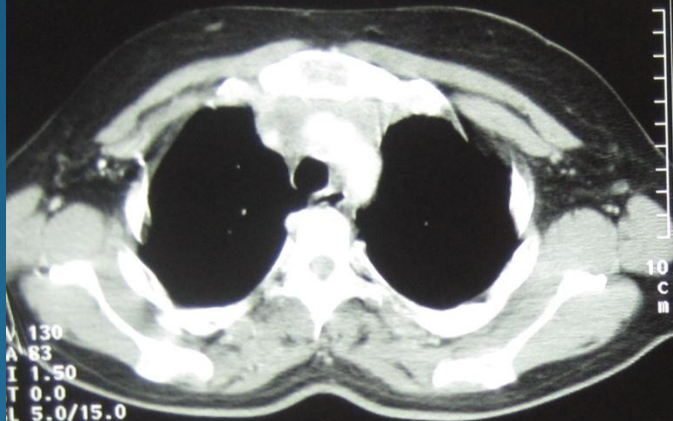
- Stade IE
- OMS = 0 LDH normale.
- Chimiothérapie + Rituximab (Mabthera)
- 6 R-CHOP

TDM(11/2011)



SEP-1979
NOV-2011
57:10.98
-303.0
14
4

H-SP-CR



kV 130
mA 83
TI 1.50
GT 0.0
SL 5.0/15.0
312 -12/0
AB50 S0
121S0>0

W 350
C 50

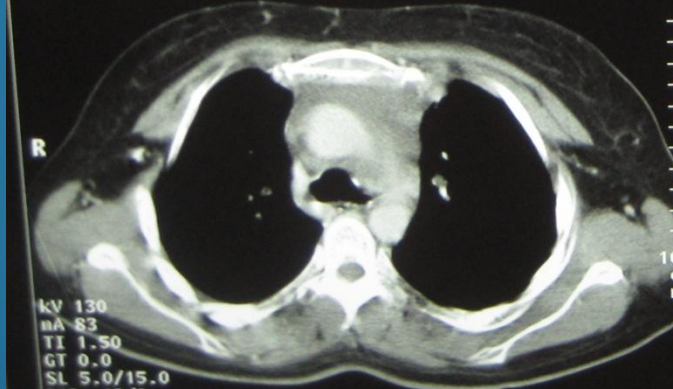
A.P.C

SANA ABDESSLEM

3764-11
15-SEP-1979
03-NOV-2011
09:57:12.98
TP -323.0
IMA 18
SPI 4

A

HOP.REG.GABES
SOMATOM AR.STAR
VB41A
H-SP-CR

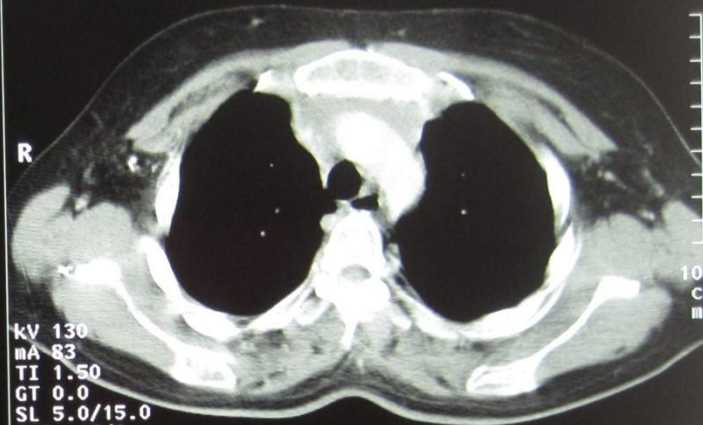


kV 130
mA 83
TI 1.50
GT 0.0
SL 5.0/15.0
312 -12/0
AB50 S0

W 350
C 50

R

03-NOV-2011
09:57:11.48
TP -308.0
IMA 15
SPI 4



kV 130
mA 83
TI 1.50
GT 0.0
SL 5.0/15.0
312 -12/0
AB50 S0
121S6>0

W 350
C 50

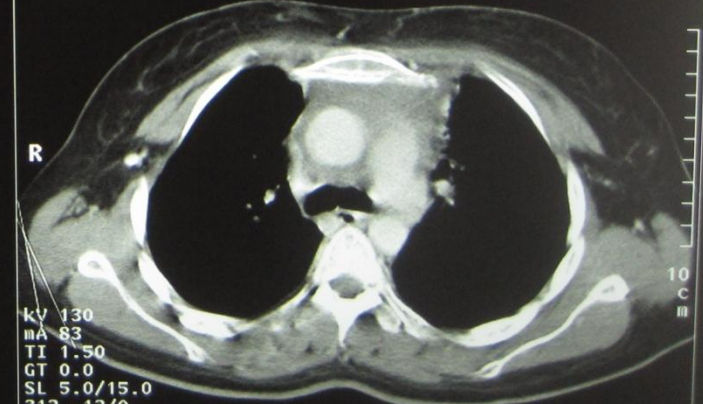
A.P.C

SANA ABDESSLEM

3764-11
15-SEP-1979
03-NOV-2011
09:57:13.48
TP -328.0
IMA 19
SPI 4

A

HOP.REG.GABES
SOMATOM AR.STAR
VB41A
H-SP-CR

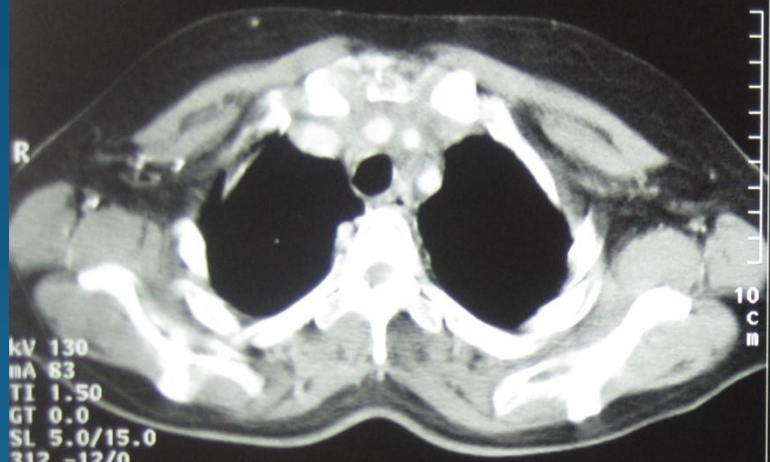


kV 130
mA 83
TI 1.50
GT 0.0
SL 5.0/15.0
312 -12/0
AB50 S0

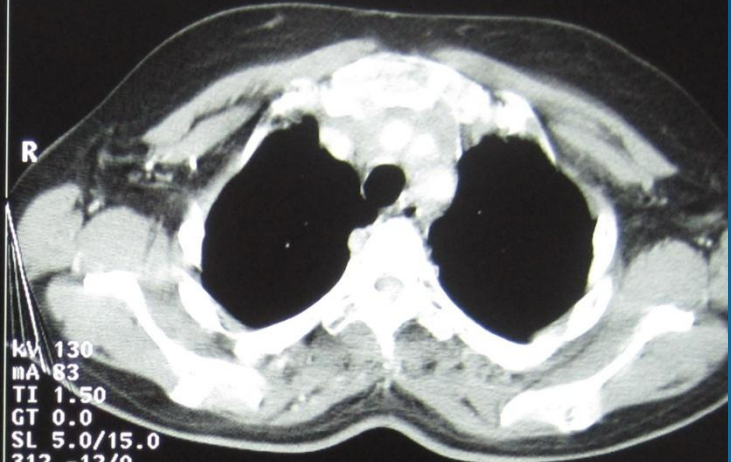
W 350
C 50

R

09:57:09.98
TP -293.0
IMA 12
SPI 4



09:57:10.48
TP -298.0
IMA 13
SPI 4



kV 130
mA 83
TI 1.50
GT 0.0
SL 5.0/15.0
312 -12/0
AB50 S0
121S6>0

A.P.C

W 350
C 50

kV 130
mA 83
TI 1.50
GT 0.0
SL 5.0/15.0
312 -12/0
AB50 S0
121S3>0

A.P.C

W 350
C 50

SANA ABDESSEM
3764-11
15-SEP-1979
03-NOV-2011
09:57:11.98
TP -313.0
IMA 16
SPI 4

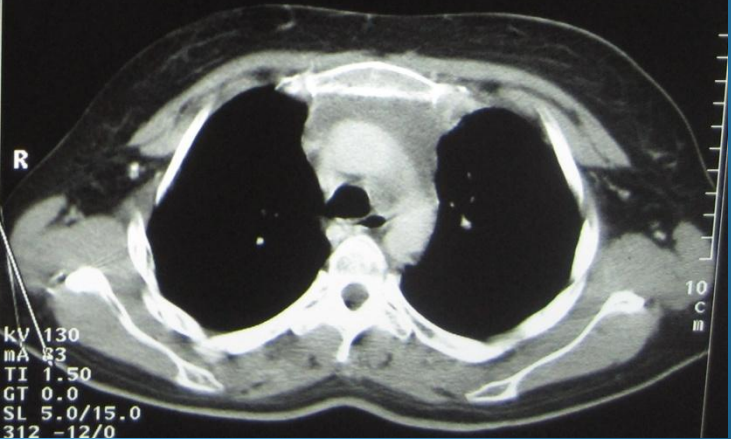
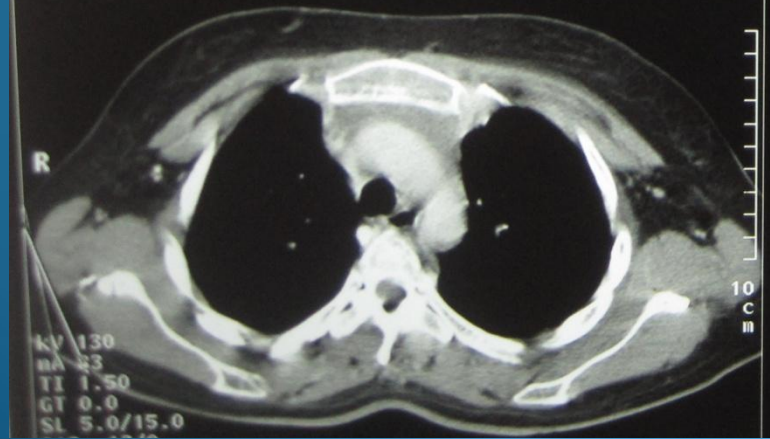
A

HOP .REG. GABES
SOMATOM AR. STAR
VB41A
H-SP-CR

SANA ABDESSEM
3764-11
15-SEP-1979
03-NOV-2011
09:57:12.48
TP -318.0
IMA 17
SPI 4

A

HOP .REG. GABI
SOMATOM AR. STAR
VB41
H-SP-CR

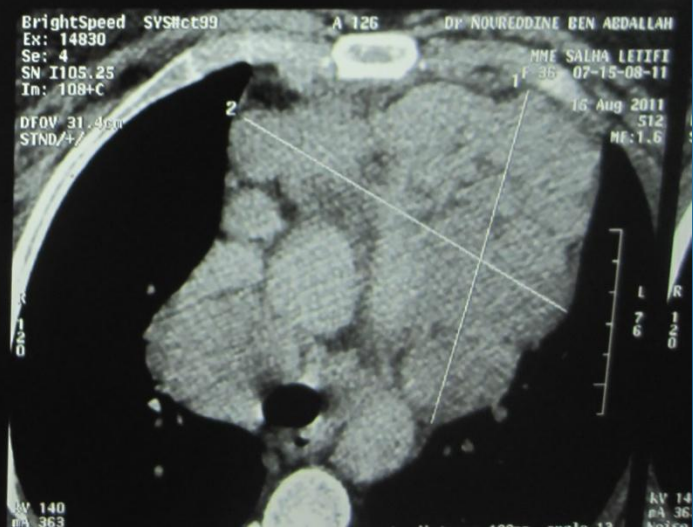
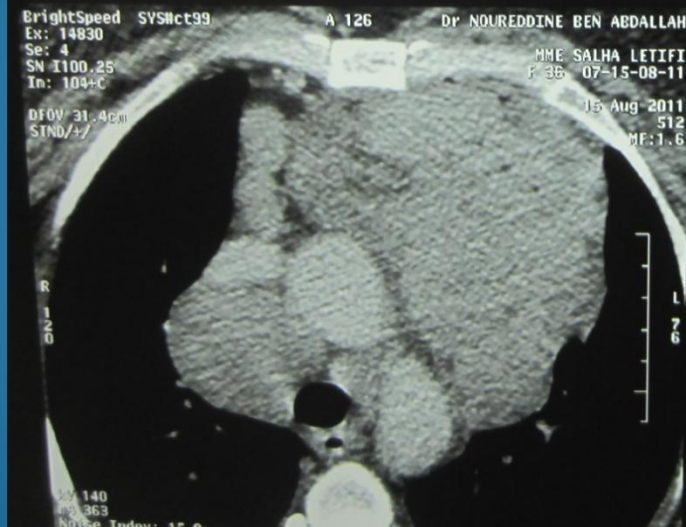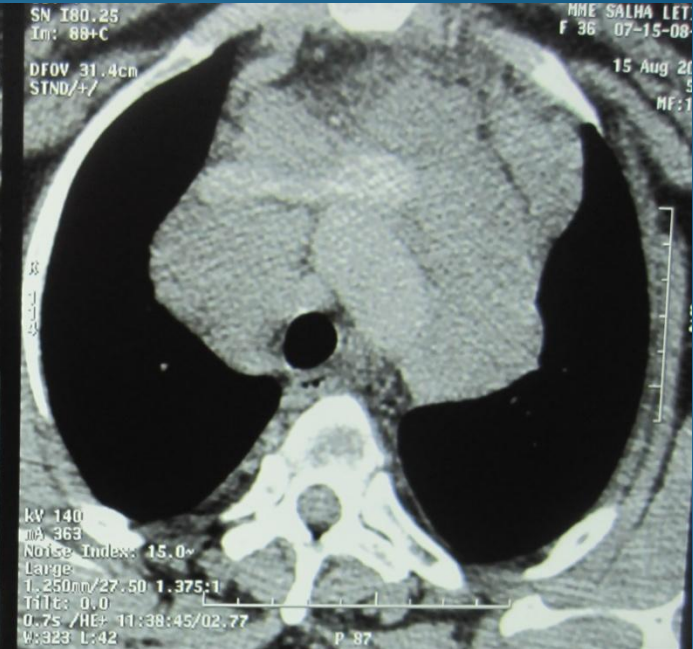

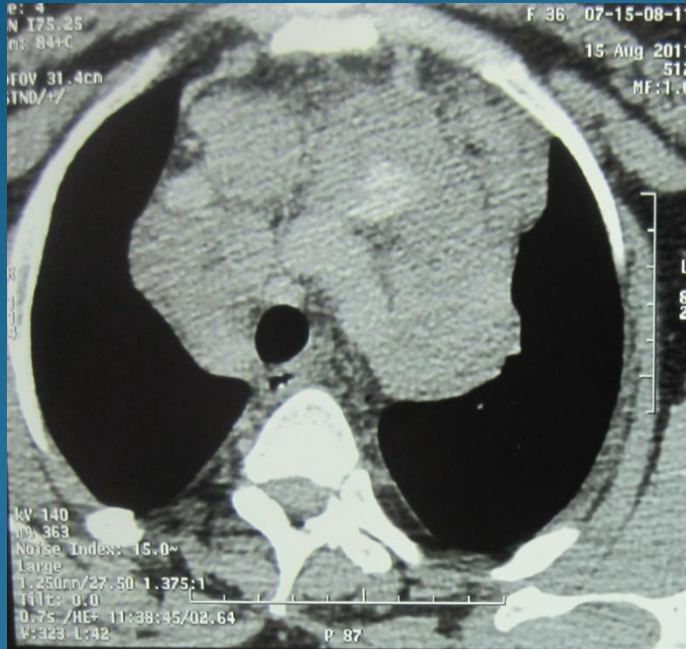
kV 130
mA 83
TI 1.50
GT 0.0
SL 5.0/15.0
312 -12/0

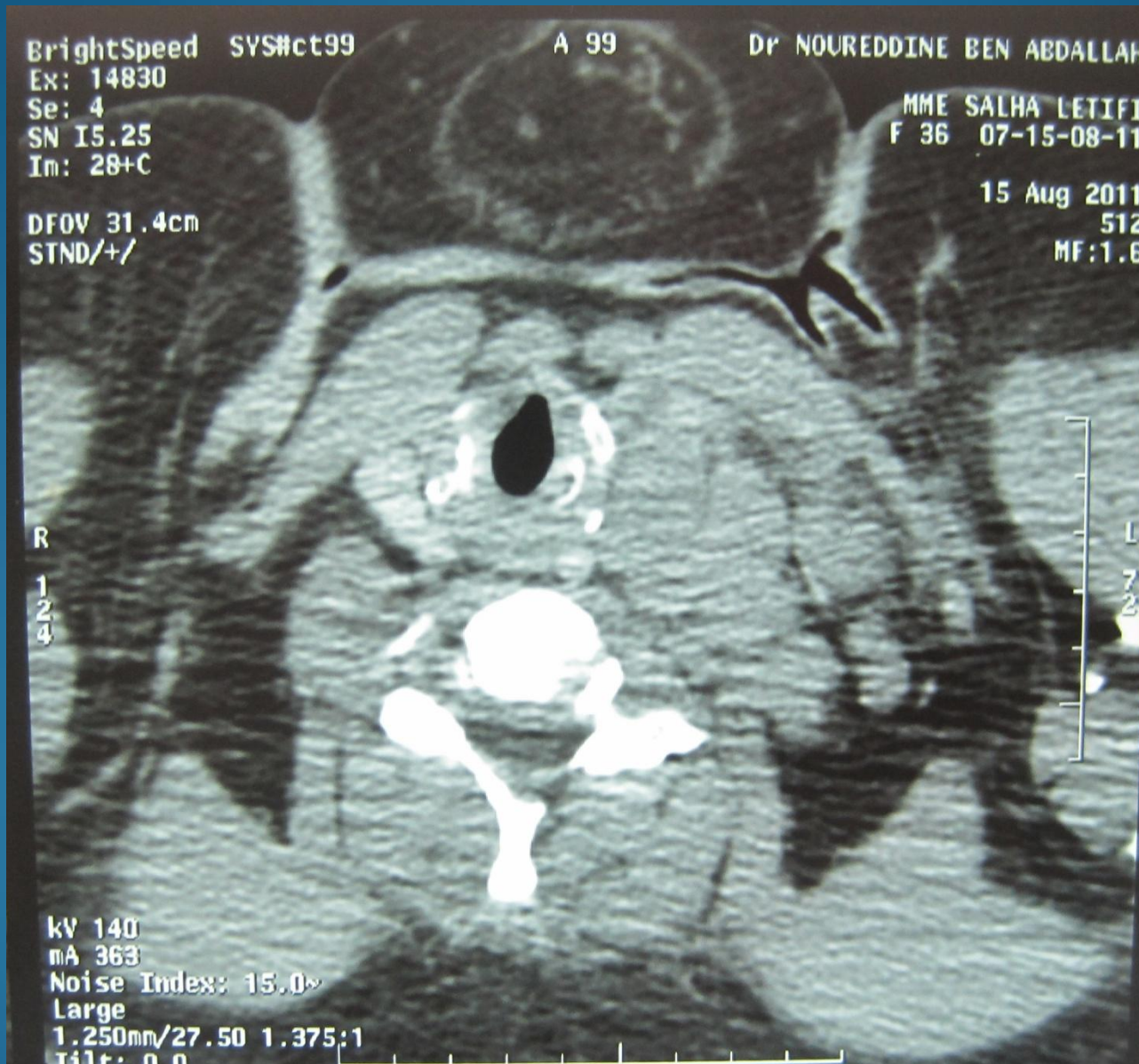
OBSERVATION 3

- Mme S.L agée de 36 ans.
- Originaire de Gabès.
- Magma ganglionnaire sus claviculaire gauche.
- Rx thorax: élargissement du médiastin
- Biopsie du ganglion sus claviculaire gauche

Scanner initial (Aout 2011)



Scanner initial (Aout 2011)



- **Lymphome anaplasique de type T CD30+
du médiastin**

Loc ganglionnaire cervicale et médiastinale

Abdomen et pelvis normaux

Biopsie médullaire: infiltrée par le lymphome

Stade IV

Chimiothérapie CHOP 14: 6 cures

Après chimiothérapie (novembre)

